

THE ARCHAEOLOGICAL EVIDENCE OF TREPANATION IN EARLY CHINA

HAN Kangxin and CHEN Xingcan

Institute of Archaeology, Chinese Academy of Social Sciences, Beijing, China.

Email: chenxingcan@hotmail.com

Keywords: trepanation, early China, Neolithic, Bronze Age, Iron Age

ABSTRACT:

Six clinically trepanned cranial specimens from five Chinese archaeological sites ranging from 5000 to 2000 BP are briefly described. They come from Neolithic, Bronze and Iron Ages sites in Shandong, Qinghai, Henan and Heilongjiang provinces. The successfully trepanned examples described in this paper reveal that this primitive surgical operation had remarkable therapeutic effects. The earliest example in this study is that of the Dawenkou individual from about 5000 BP. The meticulous treatment revealed by this operation is most impressive.

INTRODUCTION

In the last few years, the second author has collected archaeological data on cranial perforation in prehistoric China. The majority of the perforated specimens were a result of combative injuries or the acquisition of bone fragments from pre-deceased persons for demonic and magical reasons. Nevertheless, some specimens might be attributable to trepanation (or trephination) for healing purposes (Chen and Fu 1996).

The practice of trepanation was also common in some other parts of the world. In Europe, modern documentation of trepanation can be traced back to the eighteenth century. Given the surgical conditions at the time, it is not difficult to imagine the risk involved. It thus caught the attention of the general public and a fair number of records were made (Brothwell and Sandison 1967). The first step in the procedure was to remove the soft tissue at the surgical location, exposing the skull cap. Then a piece of calvarium was removed by scraping, incising or drilling with primitive surgical tools, without damage to the underlying blood-vessels, meninges and brain.

Early documentation of this surgical procedure includes records from Classical Greece (Oakley *et al.* 1959). About one century ago, anthropologists observed the practice of trepanation in Peru (Steinbock and Stewart 1967). In the last few decades, many archaeological specimens of trepanation have been studied, for instance by Lisowski (1967), Piggott (1940), Stewart (1956), Wölfel (1937) and Wehrli (1937). Trepanned specimens have come from sites in Europe, the Pacific, the Americas, Africa and Asia and range in date from the Neolithic and early Metal Age to modern times (Piggott 1940).

During our physical anthropological study of archaeological assemblages of human remains, the authors of this paper observed several clinically trepanned cranium specimens. They come from Neolithic, Bronze and Iron Ages sites in Shandong, Qinghai, Henan and Heilongjiang (Figure 1).

1. M382 cranium, Fujia site, Guangrao, Shandong

This is the earliest trepanned specimen so far discovered in prehistoric China. It is an adult male skull belonging to the Dawenkou culture, dated by radiocarbon to about 5000 B.P. There is a large round-edged and round-shaped perforation in the parietal region. Its maximum longitudinal and latitudinal lengths are 31 and 25 mm, respectively. The borders of the openings are relatively smooth and become increasingly thin toward the opening. They are an indication that the patient recovered from the surgery and lived for a long time before he died (Figures 2 and 3) (Xie 2003:12-14).

2. M70 cranium, Yangshan burial site, Minhe, Qinghai

This adult male skull belongs to the Banshan-Machang culture, dated by radiocarbon to about 4000 B.P. There is a large round-edged and triangular-shaped perforation in the parietal foramen region. Its maximum longitudinal and latitudinal lengths are 42 and 33 mm, respectively. The border of the opening is relatively smooth and the growth of tiny bone spurs can be easily seen. The perforation is embedded in a "halo" of scraping scars about 8 mm wide. The surface of the "halo" is smooth and becomes increasingly thin toward the opening (Figure 4).

It is evident that the deceased also suffered from injuries when alive. The skull exhibits two other depressions caused by bone fracture. The first is located on the right cranium between the cranial tuber and the coronal. The depression is elongated and olive-shaped, maximum length 36 mm and maximum width 17 mm. The fracture line looks dull and blurred, indicating that the patient survived the wound and the bone healed. A small circular opening (5 mm radius) can still be seen at the end of the fracture line. The perforation is divided into two halves by the growth of a bone spur (Figure 5).

The second depression is located between the sagittal crest and the upper part of the cranial tuber. Its longitudinal length measures about 14 mm., and its latitudinal length is about 22 mm. The maximum depth of the

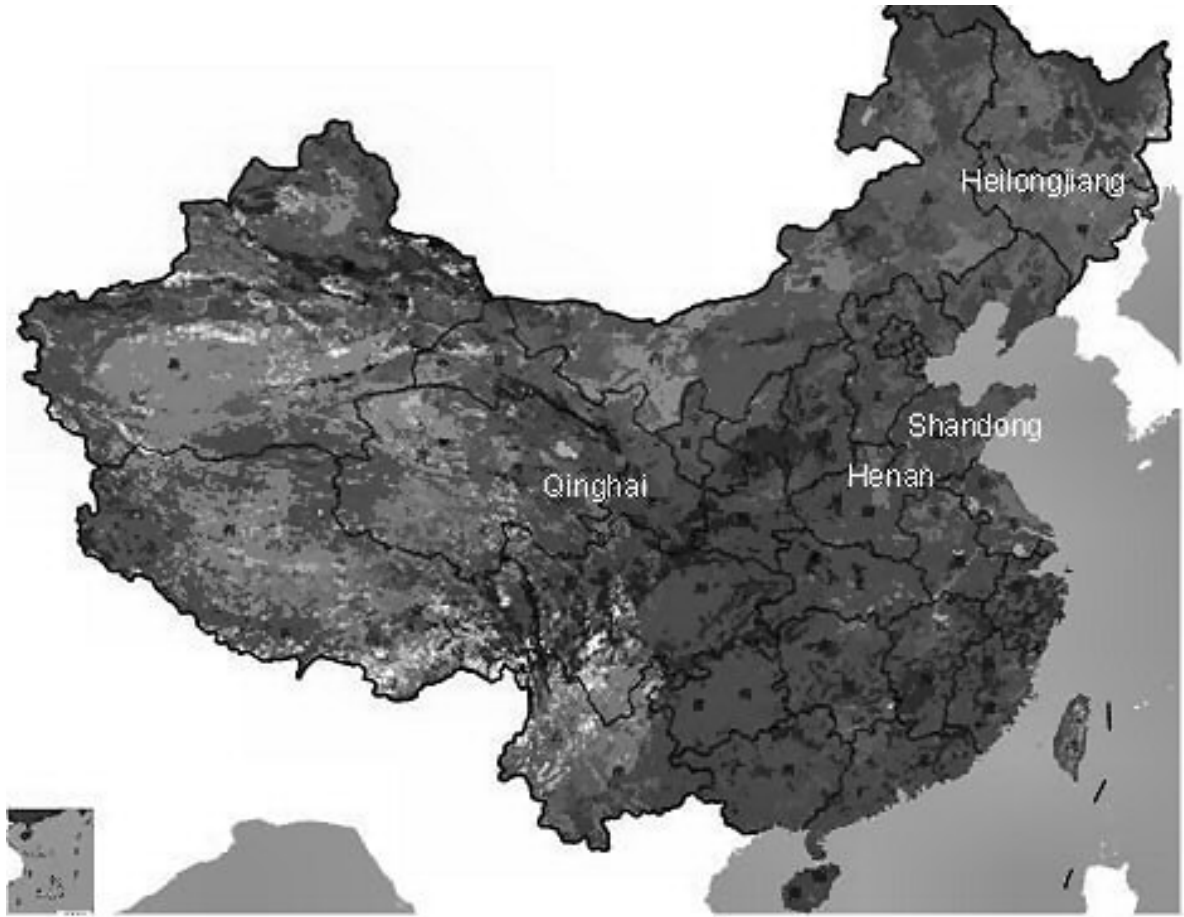


Figure 1. Archaeological discoveries of trepanation from prehistoric China.

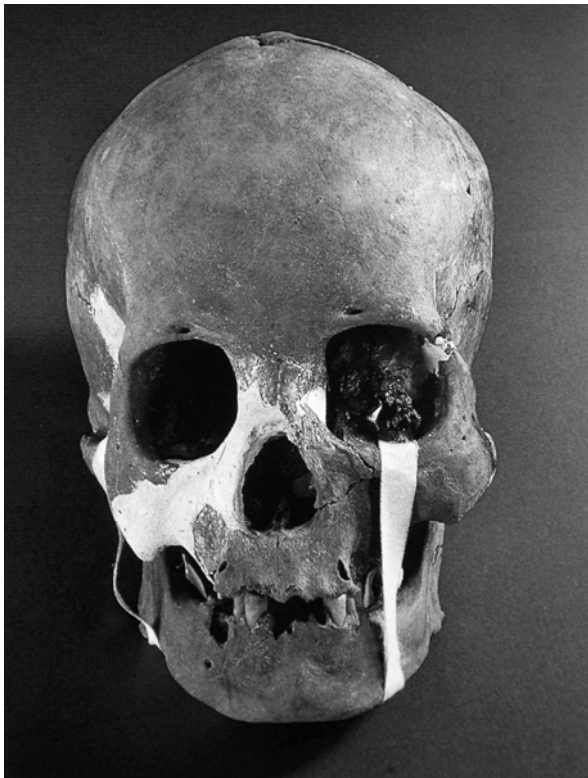


Figure 2. M382, Fujia, Guangrao, Shandong.



Figure 3. M382, Fujia, Guangrao, Shandong (top view).

depression is about 8 mm. Observing from the inside of the skull, this depression protrudes inwards and signs of healing can be seen along the latitudinal sides. There remains the trace of a small healed puncture hole at the front of the depression (Figure 5).

We interpret that the latter two of the three perforations of this specimen were bone fractures attributable to blows from blunt objects. Both have traces of small openings, indicating that the victim suffered from infection

because of the wounds. On the other hand, the triangular perforation is very likely the remains of trepanation surgery. The growth of bone spurs on the borders of the opening and the blurred “halo-shaped” scraping surface indicate that the patient recovered from the surgery. The motive for the trepanation surgery was probably related to the fracture wounds of the individual.

3. M41 cranium, DS Area A, Shangsunjiazhai burial site, Datong, Qinghai

The specimen is a young adult male of the Han dynasty, dated to about 2000 B.P. An arch-shaped incised perforation is located between the upper part of the left orbit and the superciliary arch. The perforation cut into the orbit. The longitudinal length of the opening measures about 20 mm. The maximum vertical height is about 5 mm. The borders of the cut have become smooth, although the inner corner of the upper orbit reveals possible remains of bone fracture as a result of the cutting. It worth mentioning that there is a nine millimeter long irregular-shaped non-injury related (pathological) perforation located on the front part of the inner corner of the orbit. Thus, this opening should relate to the pathological deformation of the frontal antrum. It is likely that the trepanation on the orbit was made to treat infection of the frontal antrum. The characteristics of the cutting surface and the smoothed borders of the trepanation suggest that the specimen survived the surgical operation and lived for a period of time afterwards (Figures 6 and 7).

4. M392 cranium, Shangsunjiazhai burial site, Datong, Qinghai

The specimen is a mid-age male specimen of the Kayue culture, radiocarbon dated to about 3000 B.P. This is a rare massively trepanned specimen. The trepanation opening starts just above the left temporal squamosal. It stretches across the frontal edge, and finally ends about 20 mm above the right temporal squamosal. The perforation looks like a belt with irregular borders, running across the mid-front part of the cranium. The widest area, about 30 mm wide, lies close to the right portion of the sagittal crest. The straight line maximum extent of the trepanation is 115 mm, while over the skull surface it is 155 mm.

The borders of the opening are relatively smooth. The external plate becomes increasingly thin towards the trepanned opening, giving the plate a gentle slope. This thinning is likely to be a result of using a scraping tool. The width of the scraped slope is not uniform. It is widest in the centre, about 20 mm, and narrowest at both ends, only a few millimeters. Some areas of the scraped slope look dull and smooth. Nevertheless, traces of scraping can still be clearly seen in some areas. It is interesting to point out that the external plate near the centre of the front border shows evidence of secondary growth and thickening at the edge of the opening. On the contrary, there is no indication of scraping, secondary growth and thickening on the internal plate.

In addition, there are two apparent trepanned holes in this specimen. A depression is located near the left part of the frontal edge. A semi-circular perforation (radius 4

mm) can be seen at the rear border of this depression. The second perforation is located on the right side of the cranium near the sagittal crest. This is also semi-circular in shape but is much larger (about 7 mm). The edges of this opening are relatively smooth and bone spurs have grown (Figures 8 and 9).

According to the above observations, we tentatively argue that the perforation of this skull indicates that:

- (1) The differential slope of the external plate near the perforated opening, and the lack of this slope on the internal plate, support the proposition that this massive perforation was not pathological, but artificial. The possibility of a surgical operation is high;

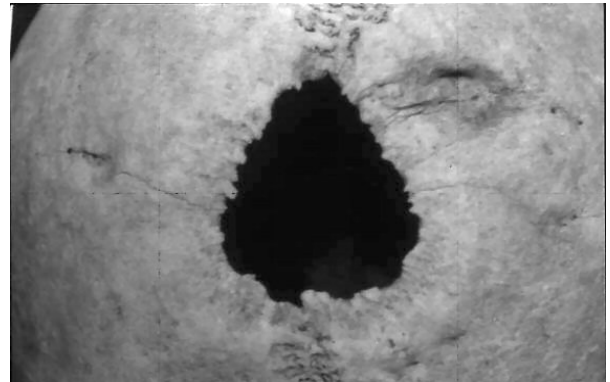


Figure 4. M70 cranium, Yangshan, Minhe, Qinghai (top view).

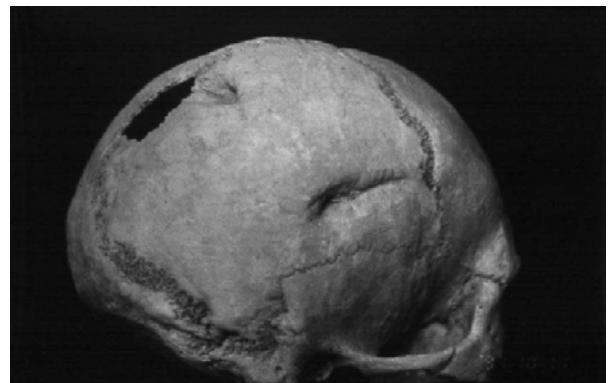


Figure 5. M70, Yangshan, Minhe, Qinghai (side view).

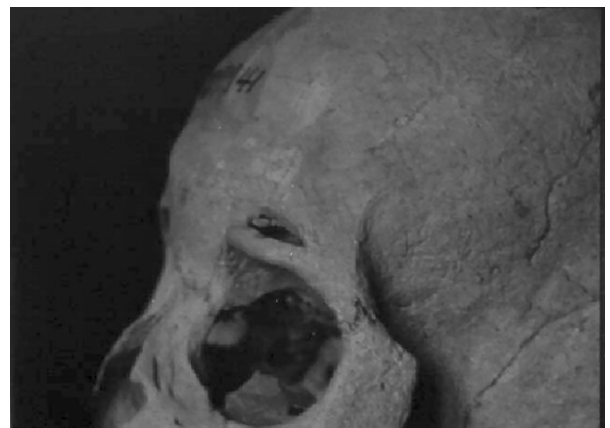

Figure 6. M41, DS Area A, Shangsunjiazhai, Datong, Qinghai.

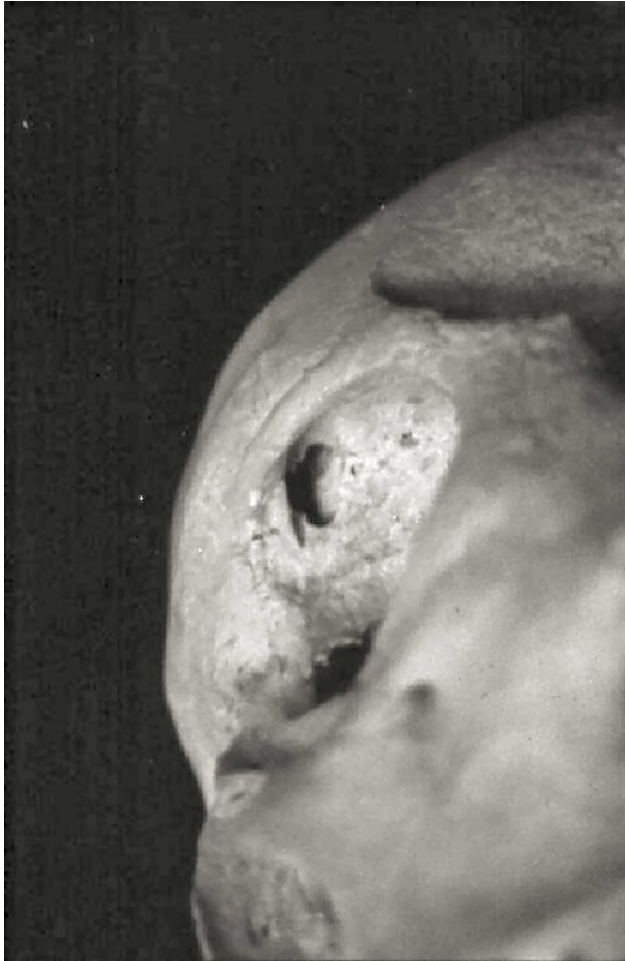

Figure 7. M41, DS Area A, Shangsunjiazhai, Datong, Qinghai. The inner corner of the upper orbit reveals possible bone fracture during the cutting process.

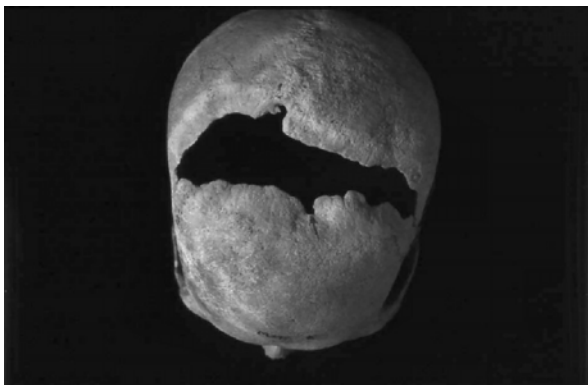

Figure 8. M392, Shangsunjiazhai, Datong, Qinghai (upper view).

(2) The smoothed surface of the sloping area, the secondary growth and thickening, and the bone spur regrowth on the borders of the opening all suggest that this person survived massive surgery. This is a remarkable successful example of prehistoric trepanation;

(3) Each of the front and the rear borders of the trepanation exhibits a small hole. They are likely to be wounds, and could well be the major reason why this individual received the trepanation operation;

(4) In general, the secondary growth on the left is stronger than that on the right. The bone spur regrowth at the front of the wound is stronger than that at the rear. It is particularly interesting that the scraping surface is particularly clear and lacks evidence of secondary growth of bone spurs at the rear right of the wound border. We speculate that more than one operation was performed on this individual, and that there was a time lapse between operations.

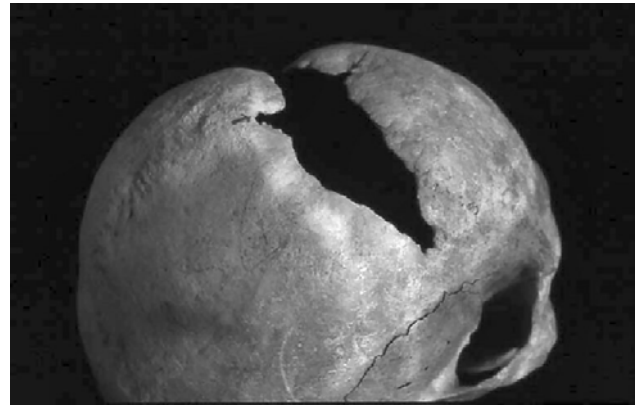

Figure 9. M392, Shangsunjiazhai, Datong, Qinghai (upper side view).

5. M11:4 (84TP) cranium, Pingyang cemetery site, Tailai county, Heilongjiang

This specimen is that of a mature adult male dated to the early Iron Age, slightly older than 2000 B.P. A small elongated perforation is located at the centre of the frontal tubers. The dimensions of the opening are 6 mm by 3 mm. The most remarkable observation from this specimen is that there are two rings of scraping scars angling into the opening. The angle of the outer ring is evidently smaller than that of the inner ring. The maximum radius of the outer ring is 19 mm, the inner ring 8 mm. The surface of the external plate of these two rings has been smoothed. The edges of the wound also look smooth;

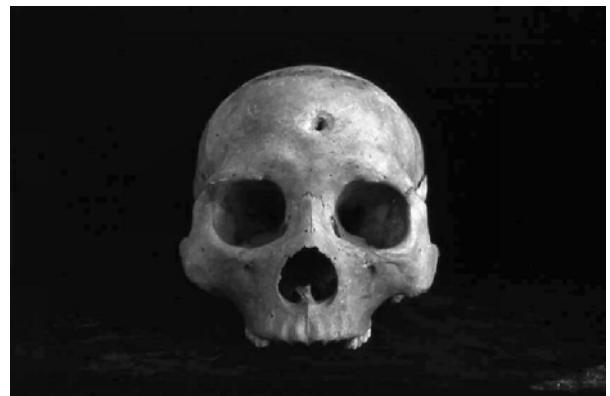

Figure 10. M11:4 (84TP), Pingyang, Tailai County, Heilongjiang.

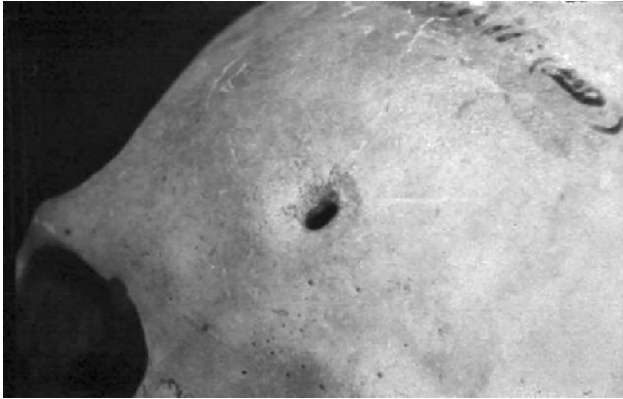

Figure 11. M11:4 (84TP), Pingyang, Tailai County, Heilongjiang.

however, no regrowth of bone spur can be observed (Figures 10 and 11).

The formation of this perforation is likely to have been caused by the intrusion of a sharp object like an arrowhead, rather than being pathological. The rings of scraping scarring embedding the perforation apparently resulted usage of scraping tools. The scraping surface and the edges of the wound are relatively smooth, indicating that the individual survived the operation.

6. M9:7 cranium, Hougang, Anyang, Henan

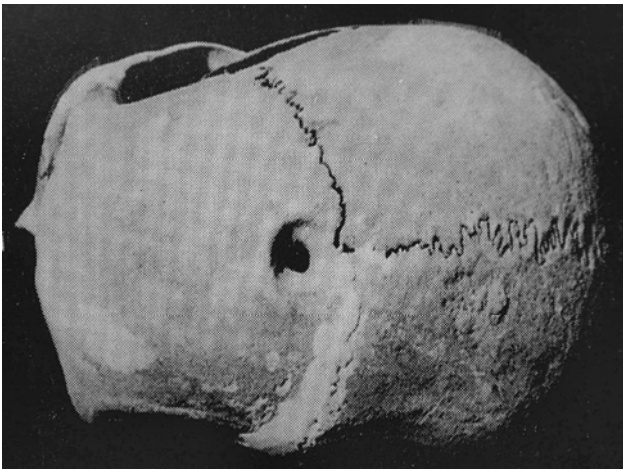


Figure 12. M9:7, Hougang, Anyang, Henan.

This adult male was a human sacrifice of the Bronze Age, slightly older than 3000 BP. A perforation is located in the middle of the frontal bone close to the coronal line. The interior radius is about 7 to 8 mm, while the exterior radius ranges between 18.5 and 19.5 mm. The wall of the perforation, therefore, slopes gradually from the outside to the inside. The surface of the cutting is smooth and dull, and the interior edges of the opening lack evidence of bone chipping. The uniformity and regularity of this opening indicate that the perforation was the result of careful scraping. The method of scraping is similar to that of the above specimen from Pingyang. However, examination of the skull does reveals no traces of fracture.

There is a growth of very fine bone spurs at the front of the interior opening. It can be concluded that this perforation was a trepanation done when the person was alive (Figure 12).

DISCUSSION

The motives for carrying out such high risk surgery can be summarized as follows:

1. To obtain bone discs from people alive or dead for protection from demons;
2. Surgical therapy for head wounds, particularly skull fracture;
3. Surgical procedure to treat headache, epilepsy, insanity and Down syndrome;
4. For longevity and fashion reasons (Brothwell 1963).

According to the survey of Stewart (1958), trepanation in Peru and Melanesia was used to alleviate pressure due to haemorrhages. Acquisition of bone discs from the skulls of deceased persons for magical and shamanic purposes existed in prehistoric Europe and recent African contexts. The bone discs were polished or perforated for wearing. Studies of cranial specimens, textual documentation and surgical operation procedures in existing traditional cultures indicate that one of the most obvious reasons for undertaking such a risky procedure was to alleviate the pressure due to cerebral oedema and cerebral haemorrhage resulting from skull fracture. Many of the trepanned specimens yield evidence of bone fracture on or near the locations operated upon (Steinbock and Stewart 1967). The several specimens in our study seem to belong to this situation. Specimen 1 shows two bone fracture depressions on the immediate right-hand side of the trepanned cutting. Specimen 2 reveals a pathologically-formed hole at the inner corner of the supra-orbital part of the skull. This hole penetrates into the frontal antrum, and the trepanned cutting is located in a position ideal for draining pus. The surgical lesion, therefore, is likely to have alleviated pressure to the eye because of nasal infection. Specimen 3 exhibits traces of puncture wounds near the centres of the front and back borders of the trepan. The elongated perforation of specimen 4 is very likely a wound suffered from a blow. Specimen 5 from Hougang exhibits a similar pattern. The several specimens in our discussion here are examples related to bone fracture or disease. If our interpretation stands, the trepanation of these individuals was a kind of surgical intervention or therapy.

The surgical methods of trepanation include scraping, grooving, boring-and-cutting and incision. The most common method was probably the use of a sharp stone or metal scalpel to scrape or cut. The early date of specimen 1 suggests that stone flake might have used. The smooth cutting surface of specimen 2 indicates that a very sharp tool, perhaps a metal blade, was used.

Several scholars argue that healing is indicated by the smoothing of borders, rounding of openings, healed spongy texture and the growth of bone spurs. All our specimens unequivocally meet these criteria. They are, thus, examples of successful operations. Given the possi-

bility that no anaesthetics or sterilization were available in early times, these are amazing achievements. It has been pointed out that the success rate of trepanation in Neolithic Europe was good, especially in southern Europe. Trepanation was commonly practised in ancient Peru, where a total of 400 trepanned skulls show healed scars on 250 specimens, a remarkable 62.5% success rate. In a study of 214 trepanned specimens, Stewart observed 50% completely healed and 16% partially healed (Stewart 1958). In addition, there are examples of successful multiple operations on the same skull. The most astonishing is that of a Peruvian specimen, showing seven healed trepanned openings (Oakley *et al.* 1959).

The successful trepanned examples described in this paper also reveal that this primitive surgical operation had remarkable therapeutic effects. It is worth mentioning that the earliest example in our study is that of the Dawenkou individual from about 5000 B.P. The meticulous treatment revealed by this operation is spectacular.

ACKNOWLEDGEMENT

The original Chinese version was translated by Dr. Yun-kuen Lee and the English version has been edited by Prof. Li Liu and Prof. Peter Bellwood. We wish to thank all of them for their hard work and long-term friendship.

REFERENCES

- Brothwell, D.R. 1963. Digging up Bones: *The Excavation, Treatment and Study of Human Skeletal Remains*. London: British Museum (Natural History).
- Brothwell, D.R. and A.T. Sandison (eds.) 1967. *Diseases in Antiquity*. Springfield: Charles C. Thomas.
- Chen, X. and X. Fu 1996. A study of skull perforation in prehistoric times. *Kaogu* 11: 62-74. (in Chinese).
- Lisowski, F.P. 1967. Prehistoric and early historic trepanation. In Don Brothwell and A.T. Sandison (eds.), *Diseases in Antiquity*, pp. 651-672. Springfield: Charles C. Thomas.
- Oakley, K.P., W. Brooke, R. Akester, and D.R. Brothwell 1959. Contributions on trepanning or trephination in ancient and modern times. *Man* 59 (133):93.
- Piggott, S. 1940. A trepanned skull of the beaker period from Dorset and the practice of trepanning in Prehistoric Europe. *Proceedings of Prehistoric Society* n. s. 6(3): 112-132.
- Steinbock, R.T. and T.D. Stewart 1976. *Paleopathological Diagnosis and Interpretation: Bone Disease in Ancient Human Populations*. Springfield: Charles C. Thomas.
- Stewart, T.D. 1956. Significance of osteitis in ancient Peruvian trephining. *Bulletin of the History of Medicine* 30:293-320.
- Stewart, T.D. 1958. Stone Age skull surgery: a general review, with emphasis on the New World. *Annual Report of the Board of Regents of the Smithsonian Institution* 1957: 469-491.
- Wehrli, G.A. 1937. Die trepanation in fruheren jahrhunderten. *Ciba-Ziho* 91:15-22.
- Wölfel, D.J. 1937. Sinn der trepanation. *Ciba-Ziho* 91: 2-6.
- Xie, Zhixiu (eds.) 2003. *New Important Archaeological Discoveries in Shandong (1990-2003)*. Jinan: Shandong Wenhua Yixiang Chubanshe. (in Chinese).